

## Improving the Methods of Treatment of Combined Fractures of the Zygomatic Bone, The Wall of the Orbit and the Upper Jaw

Shukrullayeva Gulira'no Jobirovna

**Annotation:** A retrospective analysis of the results of treatment of patients with fractures of the zygomatic bone, the wall of the eye socket and the upper jaw, by osteosynthesis using mini plates. In order to prevent dislocation of the set bone fragments and deformation of the middle third of the facial zone on the side of the injury, we used a Foley catheter.

The frequency of injuries of the maxillofacial region, and in particular, damage to the zygomatic-orbital complex, both in Russia and abroad, does not decrease; on the contrary, there is an increase in the number of patients with this pathology.

In the structure of injuries of the maxillofacial region, fractures of the zygomatico-orbital complex are the second most common.

Despite the high prevalence of this type of fractures, there are still a number of errors in their diagnosis and treatment, leading to the development of injury complication. Among patients with post-traumatic deformities of the middle zone of the face, up to 25% is caused by damage to the bones of the zygomatic-orbital region

In the structure of injuries of the maxillofacial region, injuries of the zygomatic-maxillary complex occupy the first place among injuries of the middle zone of the face and range from 14.5% to 24% of all injuries of the facial skeleton. The complex anatomical and topographic connections of the zygomatic-maxillary complex with neighboring areas determine the versatility of problems in the treatment and rehabilitation of non-gunshot lesions in this area, as well as the prevention of complications.

Modern maxillofacial traumatology, becoming more high-tech, still retains a high percentage of inflammatory post-traumatic complications in the paranasal sinuses - from 30 to 85%. Among the main causes of this complication, modern authors primarily point to the high traumatism of traditional methods of fragment reposition and fixation.

The last decades have been marked by a significant increase in the number of injuries in the population, while its structure has changed towards an increase in the proportion of combined and multiple injuries. Combined injuries of the maxillofacial region occupy a special place among traumatic injuries of the human skeleton due to functional and cosmetic features. According to various authors, their frequency fluctuates. Injury to this area leads to a disorder in the function of external respiration, maintaining hypoxia; acting as a focus of enzymatic aggression, it is a source of development of purulent-infectious complications; malnutrition slows down the recovery processes of the body's functions. The main etiological factors are road traffic and criminal injuries, catatrauma.

For the period from 2021 to 2022, there were 18 patients with fractures of the zygomatic bone, orbital wall and maxillary sinus in the clinic of the Bukhara Regional Multidisciplinary Hospital. All patients with the purpose of displacement and deformation of bone fragments underwent osteosynthesis using mini-plates. Patients with fractures of the zygomatic bone, the wall of the orbit

and the maxillary sinus needed urgent surgical intervention, we proposed to install a Foley catheter with inflation inside the maxillary sinus.

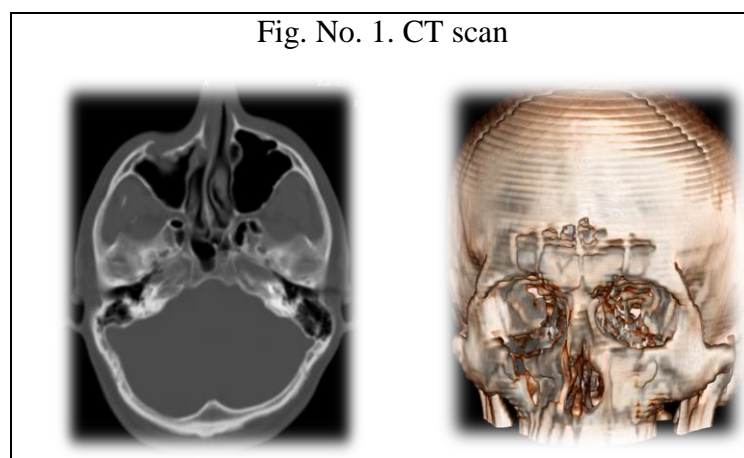
The results of treatment of 18 patients with fractures of the zygomatic bone, the wall of the orbit and the upper jaw at the age of 18-40 years. Of these, there were 13 men, and 5 women. The entire contingent of patients was admitted to the BOMC in the Department of Chest Surgery for fractures of the walls of the orbit and the upper jaw.

Depending on the damage to the fractures of the zygomatic bone and arch, the walls of the orbit and the upper jaw, the patients were divided into 2 groups:

I-th group (11 patients) injuries with fractures of the zygomatic bone and arch, walls of the orbit and upper jaw with displacement of fragments. In this group of patients, mild bleeding from the corresponding half of the nose was diagnosed, sometimes subcutaneous emphysema, hemorrhage into the tissue of the eye of the lower eyelid, chemosis; limited mouth opening.

According to a number of authors, among the surgical methods for treating fractures of the zygomatic bone and arch, the walls of the orbit and the upper jaw with a mixture of fragments, the method of repositioning bone fragments with a single-toothed Limberg hook has become widespread. However, this operation is performed extraorally. Therefore, the patients were hospitalized for a long time.

With these pathologies, after osteosynthesis with mini-plates, we use an intraoral operation according to the Caldwell-Luc method. In case of fractures of the zygomatic bone and the lower wall of the



orbit, osteosynthesis was performed using mini plates of titanium nickelide. The tube of the Foley catheter was removed from the cavity of the maxillary sinus through the nasotracheal fistula in the lower nasal passage to the outside, followed by inflating it with a balloon. The sutures on the mucous membrane of the vestibule of the oral cavity were removed on the 7th day. The catheter was removed on the 12th day. The advantage of the operation is that during the opening of the mouth, chewing food and contact of the teeth when the jaws are closed, no displacement of bone fragments is noted.

**Results and discussion.** Generalization of the results of surgical treatment was carried out on the basis of complaints of patients, external and intraoral examination, data of radiation diagnostics (radiography in semi-axial and direct projections, CT). No. 1., repeated consultations of a neuropathologist, neurosurgeon and ophthalmologist were prescribed. In some cases, endoscopic examination of the paranasal sinuses was performed.

If a fracture (Fig. No. 2.) is accompanied by a bone defect or displacement of fragments, after osteosynthesis with mini plates, we consider it rational to install a Foley catheter in the maxillary sinus cavity for a short period of 8-12 days and bring its end into the oral cavity. If the fracture is combined with damage to the bones of the nose, as well as severe deformity of the nasal septum, there are certain difficulties in passing the Foley catheter through the nasotracheal anastomosis, so its end should also be removed through the oral cavity. The withdrawn part of the Foley catheter was fixed with adhesive tape in the region of the lateral surface of the neck and supraclavicular fossa. In case of fractures of the lower wall of the orbit, the walls of the maxillary sinus, endoprosthesis is used using mini plates of titanium nickelide, as well as replantation of bone fragments. After reposition of bone fragments, we used two-way latex Foley catheters with sizes 16, 18, 22 on the Charrière scale (Ch/Fr), since these catheters are optimal in their characteristics, convenient to use, and can be easily and painlessly removed from the sinus.

**Conclusions.** Thus, the volume of surgical intervention with the installation of a Foley catheter in the cavity of the maxillary sinus in the above trauma of the facial bones directly depends on the

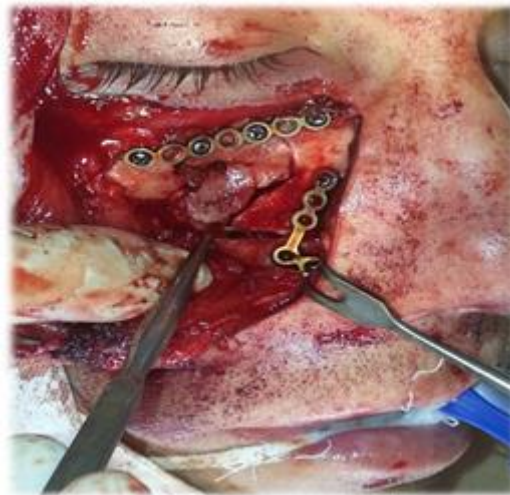


Fig. No. 2. After the installation of titanium mini plates.

degree of displacement of bone fragments, the nature of the fracture, the preservation or impairment of the functions of the eyeball, as well as the severity of pathological changes in the paranasal sinuses. The timing of surgical therapeutic measures is directly affected by the severity of damage to brain structures, severe violations of the vital functions of organs and systems, as well as the presence of diseases of a general somatic nature. Reconstructive and restorative operations



on the middle zone of the facial skull are more successful when using fixation devices made of shape memory materials, as well as their combination with titanium plates. In order to increase the efficiency and improve the results of surgical treatment, it is necessary to observe the following

condition - the reconstruction of the damaged structures of the facial skeleton to the fullest extent. It is also necessary to prevent the occurrence of traumatic sinusitis and restore the function of breathing through the nose. A multidisciplinary approach to the diagnosis of such patients and their treatment, in our opinion, is the key to the earliest possible and complete rehabilitation, which is in line with current trends.

## LITERATURE

1. С.Р. Хосе Мигель. Optimization of the algorithm for medical rehabilitation of patients with fractures of the zygomatic-orbital complex. GOUVPO "Moscow Medical Academy". - Moscow, 2011. - 95 p.
2. Ян Синь. Surgical treatment of fractures of the zygomatico-orbital complex with damage to the walls of the maxillary sinus. Moscow 2014 Abstract.
3. Г.И. Юрьева. Treatment and prevention of maxillary sinusitis in zygomatic-maxillary fractures in conditions of concomitant trauma. 2010
4. Г.К. Петрович. A modern approach to the complex treatment of combined injuries of the maxillofacial region. St. Petersburg - 2016.
5. Khodzhaeva D. I. Changes in the Vertebral Column and Thoracic Spinecells after Postponement of Mastoectomy //International Journal of Innovative Analyses and Emerging Technology. – 2021. – Т. 1. – №. 4. – С. 109-113.
6. Ilkhomovna K. D. Modern Look of Facial Skin Cancer //Барқарорлик ва Етакчи Тадкикотлар онлайн илмий журнали. – 2021. – Т. 1. – №. 1. – С. 85-89.
7. Ilkhomovna K. D. Morphological Features of Tumor in Different Treatment Options for Patients with Locally Advanced Breast Cancer //International Journal of Innovative Analyses and Emerging Technology. – 2021. – Т. 1. – №. 2. – С. 4-5.
8. Khodjayeveva D. I. MORPHOLOGY OF IDIOPATHIC SCOLIOSIS BASED ON SEGMENT BY SEGMENT ASSESSMENT OF SPINAL COLUMN DEFORMITY //Scientific progress. – 2022. – Т. 3. – №. 1. – С. 208-215.
9. Ходжаева Д. И. СОВРЕМЕННЫЕ ВОЗМОЖНОСТИ УЛЬТРАЗВУКОВОЙ ДИАГНОСТИКИ ПРИ РАКЕ КОЖИ ЛИЦА //Жизнеобеспечение при критических состояниях. – 2019. – С. 111-112.
10. Aslonov S. G. et al. Modern Approaches to Oropharyngeal Cancer Therapy //International Journal of Discoveries and Innovations in Applied Sciences. – 2021. – Т. 1. – №. 3. – С. 38-39.
11. Khodjaeva D. I. MAGNETIC-RESONANCE IMAGING IN THE DIAGNOSIS OF BREAST CANCER AND ITS METASTASIS TO THE SPINAL COLUMN //Scientific progress. – 2021. – Т. 2. – №. 6. – С. 540-547.
12. Ilkhomovna K. D. MANIFESTATIONS OF POST-MASTECTOMY SYNDROME, PATHOLOGY OF THE BRACHIAL NEUROVASCULAR BUNDLE IN CLINICAL MANIFESTATIONS //Innovative Society: Problems, Analysis and Development Prospects. – 2022. – С. 225-229.
13. Ходжаева Д. И. АНАЛИЗ СРАВНЕНИЯ МОРФОТОПОМЕТРИЧЕСКИХ ПАРАМЕТРОВ СТРУКТУР ПОЯСНИЧНОГО ОТДЕЛА ПОЗВОНОЧНОГО СТОЛБА В НОРМЕ И ПРИ

ДЕГЕНЕРАТИВНО-ДИСТРОФИЧЕСКИХ ИЗМЕНЕНИЯХ //Uzbek Scholar Journal. – 2022. – Т. 5. – С. 192-196.

14. Sulstonova N. A. Treatment of hypercoagulable conditions in women with miscarriage in early gestation //Asian Journal of Multidimensional Research (AJMR). – 2020. – Т. 9. – №. 12. – С. 13-16.
15. Султонова Н. А. ИНДИВИДУАЛЬНЫЙ ПОДХОД К ПРОГНОЗИРОВАНИЮ САМОПРОИЗВОЛЬНЫХ ВЫКИДЫШЕЙ У ЖЕНЩИН ДО 24 НЕДЕЛЬ ГЕСТАЦИИ //Современные вызовы для медицинского образования и их решения. – 2021. – Т. 406.
16. Султонова Н. А. ПРОГНОСТИЧЕСКИЕ КРИТЕРИИ САМОПРОИЗВОЛЬНЫХ ВЫКИДЫШЕЙ В СТРУКТУРЕ ПРЕВЫЧНОГО НЕВЫНАШИВАНИЯ НА РАННИХ СРОКАХ БЕРЕМЕННОСТИ НА ФОНЕ ПАНДЕМИИ COVID-19 //ЎЗБЕКИСТОН РЕСПУБЛИКАСИ СОҒЛИҚНИ САҚЛАШ ВАЗИРЛИГИ ТОШКЕНТ ТИББИЁТ АКАДЕМИЯСИ. – С. 60.
17. Султонова Н. А., Негматуллаева М. Н. Значимость Применения Витамина И Минеральной Комплексной Терапии В Профилактике Невынашивания Беременности //CENTRAL ASIAN JOURNAL OF MEDICAL AND NATURAL SCIENCES. – 2021. – С. 388-392
18. Харибова Е. А., Тешаев Ш. Ж. Морфофункциональные особенности тканевой организации энтероэндокринных клеток в возрастном аспекте //Проблемы биологии и медицины. – 2020. – №. 2. – С. 168-173.
19. Харибова Е. А. Особенности морфологии нейрональных ансамблей в тройничном узле человека //Морфология. – 2011. – Т. 140. – №. 5. – С. 123-124.
20. Махмудов З. А., Нечай В. В., Харибова Е. А. Железисто-лимфоидные взаимоотношения в стенке илеоцекального перехода на разных этапах постнатального онтогенеза //Морфология. – 2008. – Т. 133. – №. 2. – С. 85.
21. Адизова Д. Р., Адизова С. Р., Иброхимова Д. Б. Место депрессивных расстройств у пациенток с хронической сердечной недостаточностью //Биология и интегративная медицина. – 2021. – №. 4 (51). – С. 79-90.
22. Адизова Д. Р., Джураева Н. О., Халилова Ф. А. ROLE OF DEPRESSION AS A RISK FACTOR IN THE COURSE OF CHRONIC HEART FAILURE //Новый день в медицине. – 2019. – №. 4. – С. 15-18.
23. Adizova D. R. et al. Rational approach to standard therapy //Central Asian Journal of Pediatrics. – 2019. – Т. 2. – №. 2. – С. 49-53.
24. Адизова Д. Р., Иброхимова Д. Б., Адизова С. Р. Приверженность лечению при хронической сердечной недостаточности //Биология и интегративная медицина. – 2020. – №. 6 (46). – С. 112-122.
25. Kurbanovna S. I. Functioning of the Immune System in Children, After Surgical Correction of Congenital Heart Defects //European Journal of Life Safety and Stability (2660-9630). – 2021. – Т. 12. – С. 439-446.
26. Sadulloeva I. K. Ashurova NG CLINICAL AND IMMUNOLOGICAL FEATURES OF CONGENITAL HEART DEFECTS IN ADOLESCENT GIRLS //Europe's Journal of Psychology. – 2021. – Т. 17. – №. 3. – С. 172-177.

27. Тешаев Ш. Ж., Хасанова Д. А. Сравнительная характеристика морфологических параметров лимфоидных структур тонкой кишки крыс до и после воздействия антисептика-стимулятора Дорогова фракции 2 на фоне хронической лучевой болезни //Оперативная хирургия и клиническая анатомия (Пироговский научный журнал). – 2019. – Т. 3. – №. 2. – С. 19-24.
28. Тешаев Ш. Ж., Хасанова Д. А. Макроскопическое строение пейеровых бляшек тонкой кишки крысы и изменения кишки при воздействии хронического облучения //Оперативная хирургия и клиническая анатомия (Пироговский научный журнал). – 2020. – Т. 4. – №. 1. – С. 41-45.
29. Тешаев Ш. Ж. и др. Морфологические изменения лимфоидных структур тонкой кишки крыс при хронической лучевой болезни //Морфология. – 2019. – Т. 155. – №. 2. – С. 278-278.
30. ТЕШАЕВ Ш. Ж., МУСТАФОВ З. М. СРАВНИТЕЛЬНАЯ ХАРАКТЕРИСТИКА МОРФОМЕТРИЧЕСКИХ ПАРАМЕТРОВ ПОЧЕК ПРИ ПОЛИПРАГМАЗИИ ПРОТИВОВОСПАЛИТЕЛЬНЫМИ ПРЕПАРАТАМИ //ЖУРНАЛ БИОМЕДИЦИНЫ И ПРАКТИКИ. – 2022. – Т. 7. – №. 1.
31. Тешаев Ш., Худойбердиев Д., Тешаева Д. Воздействие экзогенных и эндогенных факторов на стенку желудка //Журнал проблемы биологии и медицины. – 2018. – №. 4 (104). – С. 213-215.