

MORPHOLOGICAL FEATURES OF THE GREATER OMENTUM IN PATIENTS WITH OVARIAN CANCER

Narziyeva Dilnoza Faxriddinovna, Nurov Jamshid Raxmatovich

Assistants Bukhara state medical institute, department of oncology and medical radiology

Annotation: A comparative study of the greater omentum 60 healthy women and 40 patients with ovarian cancer has done. Found that when the disease omentum reduced in size, density decreases and size of lymphoid elements. This morphological pattern indicates a decrease in the immune properties of the greater omentum.

Keywords: ovarian cancer, greater omentum, lymphoid tissue.

Among all types of malignant lesions of the female genital organs, ovarian cancer is characterized by an ambiguous prognosis and the highest mortality rates [2,6,8]. In the structure of oncological morbidity of women in the Russian Federation, the proportion of ovarian cancer is 4.9% and occupies 2-3 places among other gynecological cancers in different regions of the country [6,8].

Many authors, describing metastasis in ovarian cancer, note that one of the first places in the frequency of detection of metastases is occupied by a greater omentum. The number and volume of metastases in the greater omentum often exceeds the parameters of the maternal tumor, which can create difficulties in performing the function of the abdominal organs and can be an additional source for the spread of metastases [2,4,5,9]. However, the authors point to the lack of studies on the morphological justification of metastasis to the greater omentum, its role in the prognosis of the disease. At the same time, the role of the greater omentum as an element of the human immune system with specific lymphoid follicles - "milky spots" is known [1, 7, 10]. There is conflicting information in the literature about the need to remove the greater omentum during primary surgery for ovarian cancer [3].

All of the above determines the relevance of this problem.

The purpose of the study

Identification of morphology features of the greater omentum in women with ovarian cancer.

Materials and methods

The study was conducted in two groups: the main and control.

In the main group, the object of the study was large omentaries obtained as a result of omentectomy during operations in 60 patients with ovarian cancer.

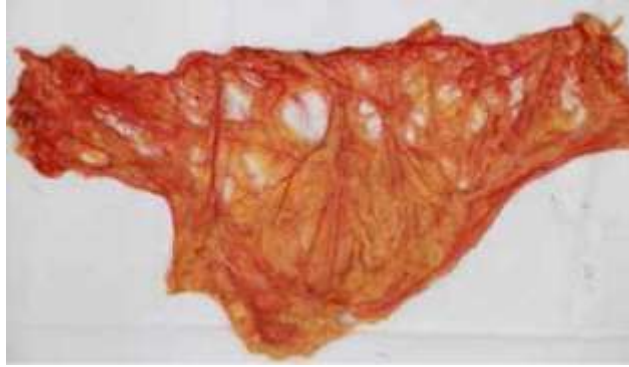The material for morphological examination in the control group was intact greater omentums taken from 40 women during autopsy in the pathology department of BSML.

Morphological examination of the greater omentum included several stages: macroscopic examination, histological examination, morphometry [5-12].

Macroscopic examination determined the shape of the greater omentum, its length and width, as well as the area. The linear dimensions of the organ were determined by a ruler with an accuracy of 1 mm (Picture 1). The area of the gland was determined by the planimetric method. For this purpose, a planimetric grid was used, which is a sheet of transparent plastic film, on which horizontal and vertical lines with a period of 1 cm were applied. When determining the area, the stuffing box was straightened on a flat horizontal surface, a planimetric grid was superimposed on top, and grid cells were counted along it. The area of the grid cells that completely fit within the boundaries of the stuffing box was taken as 1 cm². The area of the cells intersected by the boundaries of the gland (regardless of the intersection of the cell) was taken as 0.5 cm². The area of the large gland was equal to the sum of the areas of whole and intersected cells [13-19]. The number of milky spots per unit area was calculated.

ISSN 2792-3983 (online), Published under Volume: 1 Issue: 5 in October-2021

Copyright (c) 2021 Author (s). This is an open-access article distributed under the terms of Creative Commons Attribution License (CC BY). To view a copy of this license, visit <https://creativecommons.org/licenses/by/4.0/>



Picture 1. Large triangular-shaped omentum seal with uniform fat filling (norm)

Histological examination was carried out on paraffin sections and film preparations stained with hematoxylin and eosin [20-28]. The preparations were studied and photographed under the mVizo-103 microvisor microscope and the MICROMED 3 microscope with the DTM 510 camera.

The diameter of the lymphoid nodules of the omentum was studied on film preparations using a morphometric nozzle MOV-1-15x.

Results and discussion

Studies of the greater omentum in patients with ovarian cancer were carried out on organs obtained during omentectomy during surgery. The greater omentum in ovarian cancer patients differs macroscopically from the greater omentum of healthy women.

Table 1

Macroscopic dimensions of the greater omentum of ovarian cancer patients

Size	Group	Average Value M±m	Extreme	
			Smallest	Largest
Length	Control	22,4±2,6	14	33
	Experience	9,4±3,0*	5	30
Width	Control	37,8±3,7	20	42
	Experience	31,7±5,8	18	42
Square	Control	831,4±23,9	658	928
	Experience	450,5±23,9*	115,1	945,7

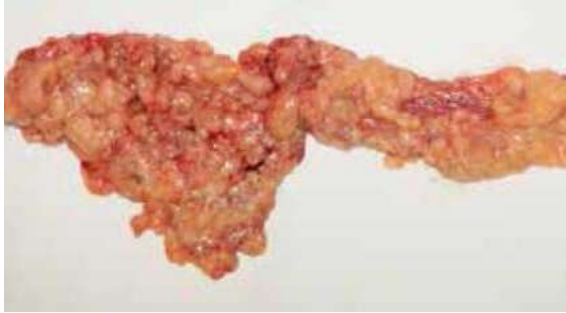*Note: * statistically significant differences from the values of the control group (p<0.001)*

Anthropometric studies of the greater omentum have demonstrated the following: firstly, the greater omentum of ovarian cancer patients has smaller dimensions (Table 1). There are statistically significant differences in the values of the length and area of the greater omentum in the experimental and control groups. The width of the greater omentum in ovarian cancer does not change significantly (p>0.05).

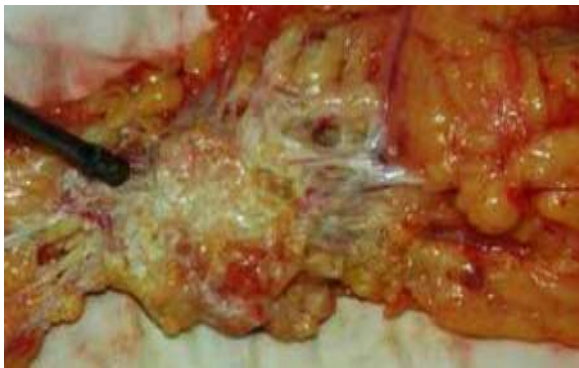Secondly, the macroscopic greater omentum of women with ovarian cancer looks wrinkled, thickened and contains relatively more fatty tissue (Picture 2). Metastases are often found in the greater omentum (Picture 3).

The histological structure of the greater omentum in ovarian cancer differs from the omentum of healthy women (Picture 4). The thickness of the loose connective tissue surrounding the vessels decreases significantly, lymphoid elements decrease or disappear. The predominant structure of the greater omentum in sick women becomes adipose tissue. Lymphoid elements between fat cells are not detected.

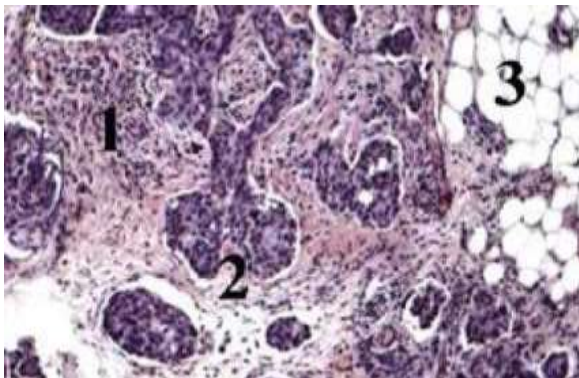
Morphometry of the lymphoid elements of the greater omentum revealed that there was a statistically significant decrease in the density and size of the "milky spots" in patients (Table 2).



Picture 2. Greater omentum of a patient with ovarian cancer. Reduction and deformation of the large oil seal is observed



Picture 3. Ovarian cancer metastasis in a greater omentum of large size. Angiogenesis around metastasis is pronounced



Picture 4. Microphoto. Lymphoid follicles (2), the environment (1) and adipose tissue (3) of the milky spot of a healthy woman. Stained with hematoxylin and eosin. Magnification x 100

Table 2

Morphometry data of lymphoid nodules ("milky spots") in the greater omentum of women

Indicator	Control group (healthy women)	The main group (patients with ovarian cancer)
Density per 1 sm ²	5,7±1,0	2,6±1,1
Dimensions, mcm	284,6±60,3	79,9±21,4

Thus, it can be concluded that the greater omentum is an organ of immune protection and up to a certain point prevents the spread of cancer cells. At the same time, the milky spots are the main site of interaction.

The ovaries are the only organ in the abdominal cavity that is not covered by the peritoneum, respectively, in ovarian cancer, adeno-carcinoma cells can freely penetrate into the abdominal cavity and circulate in it [16-23]. After some time, the dissemination of tumor cells occurs along the greater omentum.

Here there is an implantation spread, which is due to the frequent detection of metastases in the greater omentum. The capture of cancer cells is carried out by milky spots, which consist of lymphoid cells. Presumably, during the fight against cancer cells, the greater omentum undergoes some changes: a decrease in size, a decrease in the number of milky spots, deformation, a decrease in the thickness of the loose connective tissue surrounding the vessels, i.e. its reduction occurs. The decrease or disappearance of the cells of the lymphoid series indicates the depletion of the immune properties of this organ. The reduced large oil seal cannot perform its protective functions in full. In addition, the greater omentum affected by cancer cells is itself a source of further spread of the tumor process. Consequently, the modified large oil seal is subject to complete extirpation. Based on the above research results, it can be assumed that the size, condition of the greater omentum and the number of milky spots in it are prognostic factors in ovarian cancer. It also remains relevant to search for new ways to block the further spread of cancer cells in this pathology.

Conclusions

1. In ovarian cancer, the reduction of the greater omentum occurs.
2. Ovarian cancer reduces the number and size of lymphoid follicles ("milky spots") and the disappearance of scattered lymphoid elements.

List of literature

[1] Большой сальник: Пер. с англ. / Под ред. Д. Либерманн-Мефферт, Х. Уайт. - М.: Медицина, 1989. - 336 с.

[2] Бохман Я.В. Руководство по онкогинекологии: научное издание / Я.В. Бохман - СПб.: Фолиант, 2002. - 542 с.

[3] Ганцев Ш.Х. Метастазирование и лечение рака (новые данные и подходы к лечению) / Ш.Х. Ганцев // Креативная онкология и хирургия. - 2011. - №1. -URL: <http://eoncoursurg.com/?p=101> (12.05.2012).

[4] Нуров, Ж. Р. (2021). ПОСЛЕОПЕРАЦИОННАЯ АНАЛИТИКА РАННЕГО ПЕРИОДА ХИРУРГИЧЕСКОГО ЛЕЧЕНИЯ ЗЛОКАЧЕСТВЕННОЙ ОПУХОЛИ ЖЕЛУДКА. *Oriental renaissance: Innovative, educational, natural and social sciences*, 1(8), 185-191.

[5] Makhmudova, G. F. (2021). Age-related clinical, anatomical and morphological features of malignant tumors of the cervix. *Middle European Scientific Bulletin*, 12, 475-480.

[6] Turdiyev, M. R., & Sokhibova, Z. R. (2021). Morphometric Characteristics Of The Spleen Of White Rats In Normal And In Chronic Radiation Disease. *The American Journal of Medical Sciences and Pharmaceutical Research*, 3(02), 146-154.

[7] Nurboboyev A.U., Makhmudova G.F. Miniinvasive approach in the complex treatment of tumor and stone etiology of mechanical jaundice// International journal on Orange technology// Vol 3. Issue 9. Sep.2021.-P. 85-90.

[8] UmidSunnatovichMAMEDOV, J., & KHALIKOVA, F. (2021). Influence of Changes in the Intestinal Microflora after Gastrectomy and Correction Methods. *Annals of the Romanian Society for Cell Biology*, 1922-1926.

[9] Rahmatovich, N. J., & Sharofovna, K. F. (2020). LONG-TERM RESULTS OF SURGICAL TREATMENT PATIENTS WITH STOMACH CANCER. *Вестник науки и образования*, (23-2 (101)).

[10] Sokhibova, Z. R., & Turdiyev, M. R. (2021). Some Features Of Laboratory Indicators Of Micro And Macro-Elementary Condition Of The Organism Of Female Age Women Innormality And In Iron Deficiency. *The American Journal of Medical Sciences and Pharmaceutical Research*, 3(02), 140-145.

[11] Mamedov, U. S., & Pulatova, D. SH. The Results of Cancer Treatment of the Oral Caviti Tumors in. *the Republic of Uzbekistan European journal of Pharmaceutical and Medical Research*.-2019.-6 (9).-P,

ISSN 2792-3983 (online), Published under Volume: 1 Issue: 5 in October-2021

Copyright (c) 2021 Author (s). This is an open-access article distributed under the terms of Creative Commons Attribution License (CC BY). To view a copy of this license, visit <https://creativecommons.org/licenses/by/4.0/>

[12] Narzıeyva, D. F., & Jonıbekov, J. J. (2020). Morphological features of tumor in different treatment options for patients With Locally Advanced Breast Cancer. *Middle European Scientific Bulletin*, 7, 105-107.

[13] Navruzov, R. R. (2021). Characteristics of morphometric parameters of the white rat's stomach in the early postnatal period. *New day in medicine*, 2(34/3).

[14] Teshaev, S. Z., Khudoıberdıev, D. K., Dilruk, K., & Ilkhomovna, N. R. R. (2021). Morphological and morphometric changes of the stomach layer of one monthly white rats. *Journal For Innovative Development in Pharmaceutical and Technical Science (JIDPTS)*, 4(5).

[15] Navruzov, R. R. Lymphothorp therapy in the complex of treatment of purulent inflammatory diseases of the hand in outpatient conditions. *New day in medicine*, 30.

[16] FERUZA, X. (2021). CURRENT CONCEPTS OF BREAST CANCER RISK FACTORS. *International Journal of Philosophical Studies and Social Sciences*, 1(3), 57-66.

[17] М.А. Ахмадова, А.Т., Сохибова З.Р., Д.К. Худойбердиев., Ж.Р. Нуров Диагностика эхинококкоза у молодёжи на современном этапе./ Тиббиётда янги кун 2019 й.3(27)- стр 54-56

[18] М.А. Ахмадова, А.Т. Чўлиев, Ж.Р. Нуров, Д.К. Худойбердиев Лучевая диагностика эхинококкоза печени-стр./Биология ва тиббиёт муаммолари.2019, №4.2(115)с.20-25

[19] Сахибова, З. Р., & Ахмедова, М. А. К. (2021). КОМПЛЕКСНАЯ ДИАГНОСТИКА И ХИРУРГИЧЕСКОЕ ЛЕЧЕНИЕ ОСЛОЖНЕННЫХ ФОРМ ЭХИНОКОККОЗА ПЕЧЕНИ. *Oriental renaissance: Innovative, educational, natural and social sciences*, 1(8), 203-212.

[20] Mahmudova, G. F., Soxibova, Z. R., Mamedov, U. S., & Nurboboyev, A. U. (2021). FERTIL VA KEKSA YOSHLI AYOLLARDA BACHADON BO ‘UNI XAVFLI O ‘SMALARI TAHLILI (BUXORO VILOYATIDA). *Oriental renaissance: Innovative, educational, natural and social sciences*, 1(8), 175-184.

[21] NurovJamshidRaxmatovich, AhmadovaMaftuna Amin qizi. Features of Anatomy of the Greater Omentum // International journal on orange technology.– 2021. – Vol. 03(9). – P. 66-68.

[22] Мамедов, У. С., & Нуров, Ж. Р. (2020). РЕЗУЛЬТАТЫ КОМБИНИРОВАННЫХ И КОМПЛЕКСНЫХ МЕТОДОВ ЛЕЧЕНИЯ РАКА ГЛЮТКИ. *Вестник науки и образования*, (24-3 (102)).

[23] Махмудова, Г. Ф., Темирова, Д. В., & Баротова, Ш. Б. (2021). БАЧАДОН БЎЙНИ ХАВФЛИ ЎСМАЛАРИНИНГ ЁШГА ХОС ХУСУСИЯТЛАРИ. *Academic research in educational sciences*, 2(5), 186-196. <https://doi.org/10.24411/2181-1385-202100871>